



UNIVERSITAS HASANUDDIN
 FAKULTAS KEDOKTERAN
 RSPTN UNIVERSITAS HASANUDDIN
 RSUP DR. WAHIDIN SUDIROHUSODO MAKASSAR
 KOMITE ETIK PENELITIAN KESEHATAN
 Sekretariat : Lantai 3 Gedung Laboratorium Terpadu
 JL. PERINTIS KEMERDEKAAN KAMPUS TAMALANREA KM.10 MAKASSAR 90243
 Contact Person dr. Agusssalim Bukhari, M.Med.Ph.D.,Sp.GK TELP. 0812770479 e-mail: agussalim@unhas.ac.id

REKOMENDASI PERSETUJUAN ETIK

Nomor : 666 / H4.04.5.31 / PPS6-KOMETIK / 2018

Tanggal : 18 September 2018

Angka ini Menyatakan bahwa Protokol dan Dokumen yang Bertubungan Dengan Protokol
 Angka ini telah mendapatkan Persetujuan Etik :

No. Protokol	UH18000442		
Peneliti Utama	dr. Syahrirujita, Sp-THT-KL		No. Sponsor Protokol
Peneliti	Efektivitas Patch Kertas, Patch Nata De Coco dengan dan tanpa serum autologous dan heterologous Terhadap Penyembuhan Ruptur Membran Timpani Pada Ayam Petelur		Sponsor / Pihak
Revisi Protokol	2		Tanggal Revisi
Revisi PSP			3 September 2018
Lokasi Penelitian	Laboratorium Hewan Fakultas Kedokteran Universitas Hasanuddin Makassar		
Tipe Review	<input type="checkbox"/> Exempted <input checked="" type="checkbox"/> Expedited <input type="checkbox"/> Fullboard Tanggal	Masa Berlaku 18 September 2018 sampai 18 September 2019	Frekuensi review lanjutan
Anggota Komisi Etik Penelitian	Nama Prof.Dr.dr. Suryani As'ad, M.Sc.,Sp.GK (K)	Tanda tangan	
Sekretaris Komisi Etik Penelitian	Nama dr. Agusssalim Bukhari, M.Med.Ph.D.,Sp.GK (K)	Tanda tangan	

Peneliti Utama:
 Menyerahkan Amandemen Protokol untuk persetujuan sebelum di implementasikan
 Menyerahkan Laporan SAE ke Komisi Etik dalam 24 jam dan dilengkapi dalam 7 hari dan Laporan SAE
 dalam 72 jam setelah Peneliti Utama menerima laporan
 Menyerahkan Laporan Kemajuan (progress report) setiap 6 bulan untuk penelitian risiko tinggi dan
 setiap setahun untuk penelitian risiko rendah
 Menyerahkan laporan akhir setelah Penelitian berakhir
 Menyerahkan penghapusan dari protokol yang melanggar (protocol deviation / violation)
 Menyerahkan semua persetujuan yang ditandatangani

Recovery of autologous and heterologous serum plus nata de coco patch at ruptured tympanic membrane in laying hen

Syahrijuita^{1,3}, Abdul Kadir¹, Sartini², Marhaen Hardjo³, Burhanuddin Bahar⁴

ENT Department of Medical Faculty¹, Pharmacy Faculty²,

Biochemistry Department of Medical Faculty³, Public Health Faculty,

Hasanuddin University

Correspondence address: Syahrijuita :Email: syahrijuitakadir@yahoo.com

Department of ENT-HN, Medical Faculty, Hasanuddin University

Abstract

Introduction: the aim of this study to identify the efficacy of autologous and heterologous serum plus nata de coco patch at the ruptured tympanic membrane of laying hens

Method : This experimental study is performed in animals, twenty eight tympanic membranes from fourteen laying hens

Results : in autologous groups 14% (2 ears) have healed on the 2nd day and 93% (13 ears) on the 3rd day and all samples group healed on the 4th day. But in the heterologous group 64% have healed on the 3rd days and all the other samples have recovered on the 5th day. The healing times of ruptured tympanic membrane did not have a statistically significant difference at both of groups

Conclusion: The autologous and heterologous serum were recommended with nata de coco patch as alternative material application for myringoplasty and the both of them can give faster healing to the ruptured tympanic membranes of laying hen.

Keywords : Bacterial cellulosa, serum, patch, tympanic membrane

Introduction

The rupture of the tympanic membrane is a common health problem found in ENT clinics. These conditions when does not self-closing and heals sometimes require invasive surgical action with a variety of complicated and costly risks of surgery. If rupture of the tympanic membrane becomes permanent it will cause hearing loss and constraints communication resulting in social and productivity disruption.¹

Treatment of ruptured tympanic membrane with surgery are costly with various rising of risks, challenges scientists to seek a cheaper, simpler, and affordable conventional alternative for patients with miringoplasty patches utilizing various materials such as skin, paper, silk, cartilage, and others.²

Biocelulose nata de coco is a natural biopolymer grown in coconut water medium with the help of *Acetobacter xylinum*.^{3,4} The making of biocellulose by a certain method into a sheet / membrane with unique characteristics alike to human skin shows its potential to be an alternative patch on miringoplasty action. These biocelluloses have been used for various medical activities such as sanitary napkins, vascular connector and even audio membranes.^{5,6}

High water content (98-99%), good fluid absorption, low allergenicity, good biocompatibility, possibility to be sterilized without worrying about changes in shape, and its similarity with human skin make biocellulose feasible to be applied as an alternative patch for miringoplasty.⁷

In the process of tissue healing as well as on the tympanic membrane rupture, a combination of 3 factors is required: cell proliferation, platform and regulator. In the old sores stripping is required to precipitate cell proliferation at the wound edges, while the platform is performed using a moderate nata de coco patch for autologous or heterologous serum regulators as growth regulators.⁸

This study aims to identify the effectiveness of autologous or heterologous serum plus nata de coco patch in accelerating the healing of tympanic membrane rupture.

Materials and Method

This study is an experimental study on animals. Using 28 tympanic membranes of 14 laying chickens aged 72-96 weeks with an average weight of 1500-2000 grams. Using local anesthetics in the form of a 2% lidocain application prior to the rupture of the tympanic membrane using microspoon with a wound size <50% of the tympanic membrane diameter. Using a complete randomized design the samples were divided into 2 groups of 14 ruptured tympanic membranes applied with autologous serum and the other 14 were applied with heterologous serum on the wound edges followed by the application of the nata de coco patch and reassessment of each 0.2 ml serum at the top of the patch. Each treatment has computerized documentation. Examination of the rupture healing of the tympanic membrane is done daily until the sample undergoes complete healing using a digital otoscope which obtained membrane images is stored in a computerized manner for further analysis using statistical tests.

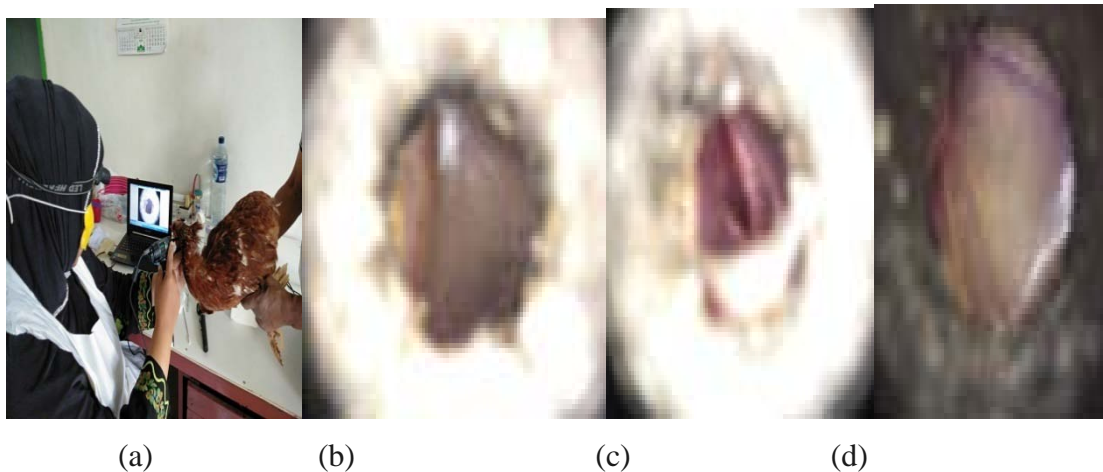


Figure 1. Application of laying hens with serum (a), Normal tympanic membrane (b), Membrane tympanic rupture (c) and Tympanic + serum + patch membrane nata de coco (d)

Results

The results of the study are :

Table 1. Comparison of healing time of tympanic membrane rupture between autologous and heterologous serum plus nata de cocopatch (NCP)

Treatment	The healing time
-----------	------------------

	1st day	2nd day	3th day	4 th day	5th day	amount
NCP + autologous serum		2	11	1		14
NCP + heterologous serum			9	4	1	14
Total		2	20	5	1	28

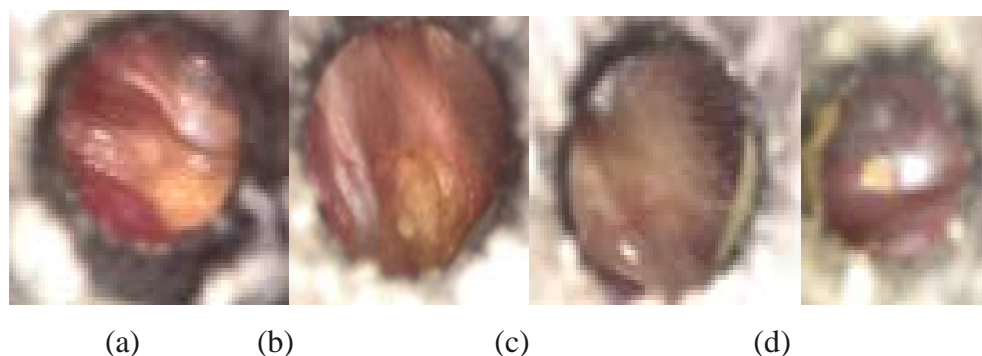


Figure 2. Visual of tympanic membrane based on time. The healing of the 2nd day (a), 3th day (b), 4th day (c), 5th day (d)

Discussion

By day 2, 28% (2 tympanic membranes) of the ruptured tympanic membrane by using NCP + autologous serum had closed, on the 3rd day it was 93% (13 tympanic membrane) and on day 4 all tympanic membrane had complete healing. NCP + heterologous serum group has occurred closure and healing by day 3 on 9 tympanic membranes (67%), 13 (93% closed on day 4 and 100% (13 tympanic membrane) have undergone complete closure on day 5. This means that within 5 days the overall sample of both autologous and heterologous groups has undergone complete closure and healing. It appears that in the NCP plus autologous serum group healed a day faster in healing than in NCP plus heterologous groups, although statistically it is not significant, or in other words both NCP plus autologous serum or NCP plus heterologous can be recommended for use in expediting the healing of the tympanic membrane rupture.

This is in line with Kim et al's (2013) study which shows that the use of bacterial cellulose patches with mannitol media is faster in healing compared to controled mice although complete healing and closure can be seen on day 7 with 3 (27.3%) tympanic membranes . And all perforation of the tympanic membrane will close on day 14 (2 weeks).⁹

In this study, complete healing and closure time of transient rupture membranes was 9 days faster than those conducted by Kim et al. This condition is possible because of the difference of animals used in research where the Kim et al use white mice while we are using laying hens. And while research by Kim et al only use patform bacterial cellulose from mannitol media, we use bacterial cellulose with coconut water media plus usage of autologous serum and heterologous serum.

In this study we found the fact that autologous serum and heterologous serum in addition to the bacterial cellulose platform increased the speed of healing of the ruptured tympanic membrane by almost 2 times.

In this study also obtained the scientific fact that the autologous serum and heterologous serum does not differ significantly in accelerating the healing of tympanic membrane rupture, so that in later application in humans the use of serum as a growth regulator may be obtained from either the patient alone or the serum of others.

When on the various searches of patch material like silk, chitosan can be filled with various ingredients of growth regulator like EGF etc, then from this research note that PNC later can be combined with various growth factors other than serum.

Conclusion:

The results of this study indicate that there is no significant difference in the effectiveness of NCP plus autologousserum orNCP plus heterologous serum in accelerating the healing rupture of the tympanic membrane. This study recommended both heterologous and autologous serum combinations withNCP for later applications as an alternative material that can be applied for miringoplasty action due to the rupture and perforation of the tympanic membrane.

Ethical clearance- Taken from medical faculty ethical clearance committee

Source of funding- Author her self

Conflict of Interest –None

REFERENS

- 1.Syahrijuita, Sartini. Characteristic of Bioselulosa *Nata de Coco* for Miringoplasty Patch.Presented : 11th Scientific Otology Meeting, ,Makassar, August 11-13,2017
- 2.Silviera FCA,PintoFCM,NetoSSC,LealMC,CesarioJ,Aguaiair JLA.Treatment of Tympanic Membrane Perforation Using Bacterial Cellulose : a Randomized controlled Trial. Braz J Otorhinolaryngol. 2016;82(5):618-619
- 3.Bielecki S, Krystynowicz A, Turkiewicz M, Kalinowska H. Bacterial cellulose. [Serial on Internet] [dikutip 7 Mei 2011]. Available from: http://www.wiley-vch.de/books/biopoly/pdf_v05/bpol5003_37_46.pdf. pp. 40-6.
- 4.Jagannath A, Kalaiselyan A, Majunantha SS, Raju PS, Bawa AS..The effect of pH, sucrose and ammonium sulphate concentrations on the production of bacterial cellulose (nata-de-coco) by *Acetobacterxylinum*. *World J MicrobiolBiotechnol*. 2008;24. pp. 2593.
- 5.Chawla PR, Bajaj IB, Survase SA, Singhal RS. Microbial cellulose: fermentative product and applications in *Food Technol. Biotechnol*;2009.47(2). pp. 107-124
- 6.Czaja W, Krystynowic A, Bliielecki S, Brown RM. Microbial cellulose—the natural power to heal wounds. *Biomaterials*.2006 ;27. pp. 145-151.
- 7.Ciechańska D.Multifunctional bacterial cellulose/chitosan composite materials for medical applications. *FibresText.in East. Eur*. 2004;12(4). pp. 69-72.
- 8.JuniartiNana.PengaruhWaktuPemanenanTerhadapProduksiBioselulosaOleh*AcetobacterXylinum*Dalam Media Air Kelapa Yang DifortifikasiDenganTehSebagaiPembalut Luka Bakar.Tesis.Makassar:FakultasFarmasi, Universitas Hasanuddin.2012. p.35-40
9. Kim J, Kim SW, Park S, Lim KT, Seonwoo H, Kim Y, et.al.Bacterial cellulose nanofibrillarpatch as a wound healing platform of tympanic membrane perforation. *Adv Healthc Mater*.2013: 2(11):1525–1531

